

## CASE NOTE

# FUSED ATLANTIC POSTERIOR ARCH HYPOPLASIA — RACHISCHISIS?

**KJ Dennison**

*Department of Anatomy and Structural Biology, University of Otago, Dunedin, New Zealand*

### ABSTRACT

Bony fusion between the skull and the vertebral column is a sufficiently rare skeletal anomaly that we may never have the opportunity to see it during our career. An 'evidential' discovery led to an example being made available for detailed study. This illustrated paper presents the findings of the study, reviews other studies, and discusses the genetic origins of such an outcome.

(*J Forensic Odontostomatol* 2009;27:2)

**Keywords:** atlanto-occipital joint, bony fusion, forensic anthropology, odontology, rachischisis

### INTRODUCTION

Knowledge of bony fusion between the cranial base and the first cervical vertebra (Figs.5,6,7) is critical for neurosurgeons, neurologists, radiologists and physiotherapists. Menezes<sup>1</sup> assesses its incidence as being 0.25% among the general population, while its incidence among Caucasoids has been reported as being 0.5 – 1.0 %.<sup>2,3</sup> According to Harcourt and Mitchell<sup>4</sup> it was first described by Rokitansky in 1884. Since then a plethora of titles has been bestowed on it - assimilation of the atlas,<sup>1,5,6</sup> atlanto-occipital fusion,<sup>7-10</sup> fusion of the atlas,<sup>11</sup> fusion<sup>12</sup> or ankylosis<sup>13</sup> of the atlanto-occipital joint, occipitalization of the atlas,<sup>3,14-19</sup> occipitocervical fusion<sup>12</sup> and occipitocervical synostosis.<sup>20</sup> This craniovertebral abnormality may involve the anterior arch of the atlas, the lateral masses, or the entire atlas,<sup>3</sup> ranging from a fibrous band uniting juxtaposed small areas of atlas and occiput, to a bony ridge, to multiple bony 'welds' as in the present case, or a complete fusion. Given the radiodensity of bone mass this craniovertebral interface is a notoriously difficult region to view. This anatomical abnormality may go unnoticed unless, given its proximity to the spinomedullary region, a

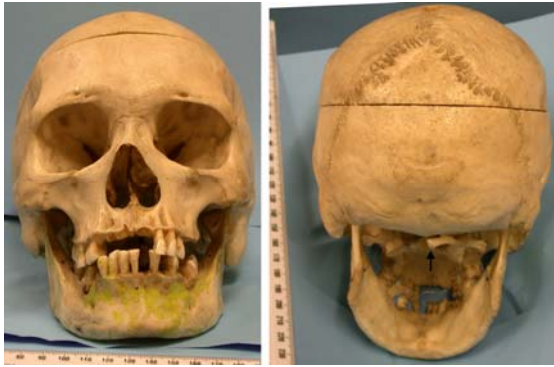patient presents with neurological compression syndrome, and a wide variety of associated signs and symptoms that may require a CAT scan or MRI<sup>21</sup> to reveal their cause. Otherwise an individual may be fortunate enough to go through life blissfully unaware of the abnormality,<sup>15,22</sup> which may then be revealed by surgery, autopsy, or commercial preparation for study. This paper describes such a case.

### MATERIALS AND METHODS

In September 2008, a human skull that had been recovered from a domestic dwelling during a New Zealand Police operation, was received for comment. The skull was assessed by gross, visual examination only. The mandible was maintained in articulation by light-gauge wire, and the accompanying first cervical vertebra was fused in three places to the occiput.

The material was generally in well-preserved condition. It had been kept in a dry state for some time - dust fibres were visible at the medial foramina of both carotid canals. The medial wall of both orbits had suffered *post-mortem* damage from hand-grasping (Fig.1). The *dorsum sellae* had been broken off after death (Fig.3), as had the pterygoid hamulus of the left side. Some teeth had been lost after death.

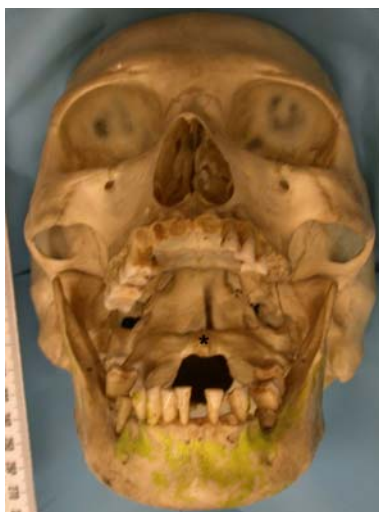The cranial vault had a drilled, round hole in the midline immediately posterior to vertex. The corresponding circular rust stain inside the vault, where a washer had been fitted, indicated that the skull had been suspended in the past (presumably with its missing postcranial skeleton). The vault had been sectioned transversely; two metal retaining pins projected from the inferior surface of the



**Fig.1:** The anterior and posterior aspects of the skull; the extremity of the atlantic right posterior arch is indicated by the black arrow.

cut (Fig.3), and slotted into corresponding holes in the superior surface. On both sides of the cut, aligned holes indicated the position of clips for securing the vault. A single smaller hole, anteriorly on each side, indicated the position of a spring for securing the mandible. The conclusion is that at some time in the past the skull had been held in an anatomical training facility or in a medical practitioner's surgery.

Subsequently, the mandible had been painted luminescent, lime green (Figs.1,2); there were red paint traces round the inferior cut surface of the cranium, and a single fleck of white paint above the larger of the two right supraorbital foramina - the 'holder' of these human remains claimed to have purchased them from a "travelling horror show" around 1986.

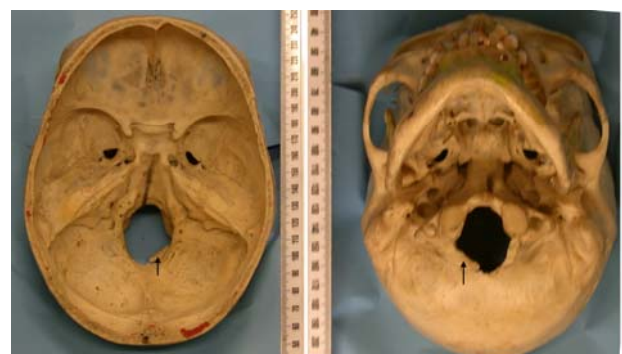

**Fig.2:** An open-mouth view, showing thinning of the orbital roof, the degree of occlusal wear, and indicating the centre of the atlantic anterior arch by an asterisk.

The skull was sexed subjectively as female, using morphological features given in standard textbooks of anatomy and forensic science.<sup>23-25</sup> At time of death she was aged in her late twenties, based on the limited occlusal wear of the three remaining molar teeth and the patent petro-occipital suture<sup>26</sup> on the left side. Given the generally gracile nature of the skull, sectioning of the vault, evidence of suspension, this skull had been prepared for teaching purposes and, in the New Zealand setting, it is therefore most likely that the individual came from continental India.

There are three small 'button' exostoses on the external surface of the cranial vault.<sup>27</sup> There is marked thinning, to the extent of translucency, of the orbital roof of both sides (Fig.2). Examination with a 5x *Lupe* eyepiece revealed some pitting anteriorly in the roof, a bony reaction to subperiosteal bleeding, earlier thought to be a symptom of anaemia<sup>28</sup> but more likely indicative of poor nutrition at some stage of her life.<sup>29</sup>

There appears to have been a marked overbite, particularly on the anterior teeth (Fig.1). There is marked dentine exposure on most of the occlusal surfaces and also interproximal attrition (Fig.2). Calculus is present. No carious lesions were observed on the remaining teeth. The 41, 42, and 43 teeth are misaligned. The roots of the 45 and 46 had been functioning as occlusal surfaces. On the buccal surface of the mandible is a bony reaction to an apical abscess of the proximal root of the 46 tooth (Fig.1).

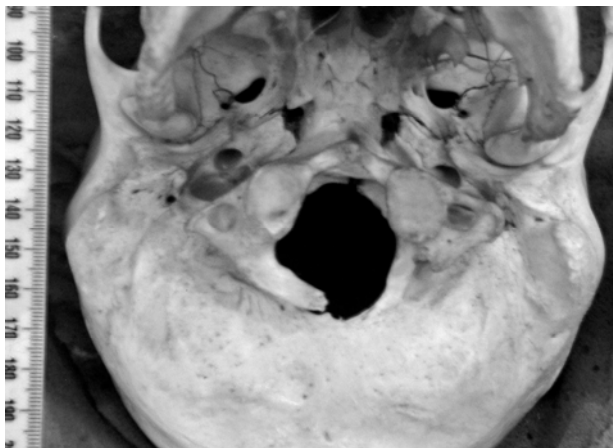


**Fig.3:** Intracranial and inferior views of the skull. Intrusion of the right atlantic posterior arch into the foramen magnum is indicated by the black arrows.

## RESULTS AND DISCUSSION

The striking feature of this skull is the bony fusion between the occiput and the first cervical vertebra.

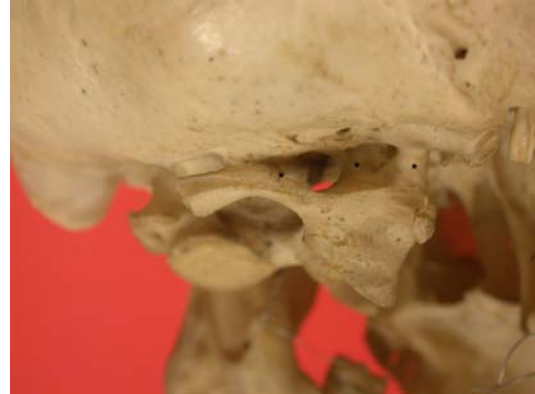Apart from a slit above the anterior arch of the atlas (Fig.6) the fusion extends, solidly, to just beyond the site of both occipital condyles. Then, approximately midway along the posterior arch of the right side, there is a further fusion site - the left posterior arch of the atlas is missing entirely. In addition, there appears to be torsion between the skull base and the orientation of the fused atlas, which is rotated slightly to the left. Its right posterior arch is encroaching markedly into the foramen magnum (Figs.3,4). The right arch terminates shortly before the midline and, when I examined the medial sagittal end of this arch, its slightly 'scooped-out' nature led me to suspect that it has never fused with its left-side partner, that is, we are looking at a case of spina bifida posterior, or posterior arch rachischisis.<sup>17,21</sup>



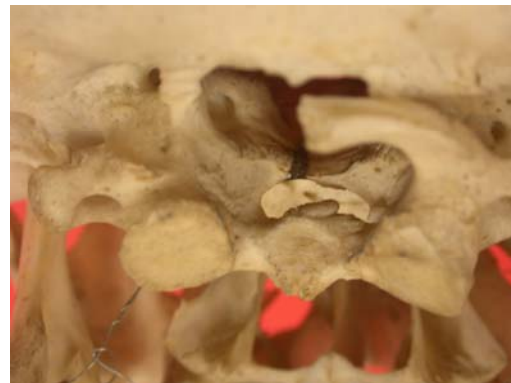**Fig.4:** Closer detail of the inferior aspect of the skull.

Contrary to the findings of Merbs and Euler,<sup>10</sup> and Nayak *et al.*,<sup>30</sup> the vertebral transverse processes do carry vertebral canals, much larger on the left side than the right (created by thinning of the anterior limb (Green's 'costal lamella'<sup>7</sup>) of the foramen transversarium), (Fig.4). Much-enlarged hypoglossal canals are present bilaterally, as are the foramina for the first cervical nerves. Within the cranial cavity the right transverse and sigmoid sinuses are larger and more deeply marked than those of the left side, a finding corroborating that of Gladstone and Erichsen-Powell.<sup>11</sup> The left condyloid canal is much larger than that on the right, and both open directly into the termination of the sigmoid sulcus (again, a corroboration of Green<sup>7</sup>). In agreement with Merbs and Euler,<sup>10</sup> the inferior atlantic condyles are larger than normal (slightly more so on the right). Both are ovoid, and slope inferomedially and posteriorly, corroborating

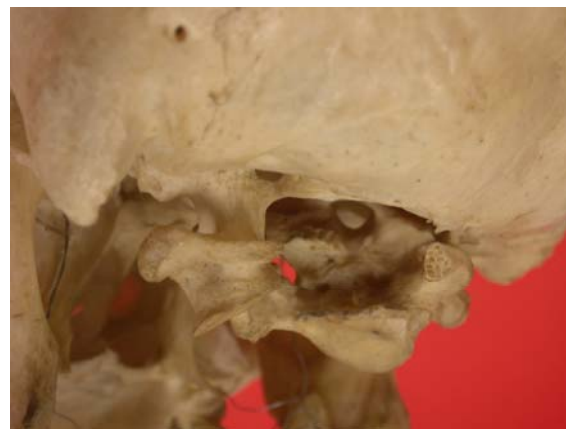both Gladstone and Erichsen-Powell's<sup>11</sup> and Green's<sup>7</sup> findings. There is a marked exostosis at the site for articulation with the odontoid process of the second cervical vertebra (Fig.6).



**Fig.5:** Right lateral aspect of the skull. The three sites of fusion of the atlas with the occiput are indicated by the black asterisks.



**Fig.6:** Posterior aspect of atlas and skull, in eccentric relationship, showing the odontoid articulation facet flanked by the inferior atlantic condyles.



**Fig.7:** Left posterolateral aspect, showing the left fusion post and an end-on view of the honeycombed, scalloped, right posterior arch of the atlas.

The earliest record of fusion between occiput and atlas, in English, that I found was an 1893 paper by Macalister<sup>5</sup> discussing various rare assimilations or 'abnormal attachments' of the atlas to the skull base and citing those found by both Langerhans and Luschka. Unfortunately the findings by Struthers, which were published in the same journal in 1874, were not cited. Thanks to the kindness of an unknown referee I have learned of this, possibly the earliest publication on this subject. In 1915 we read of a 'partial liberation of one of the vertebral elements which normally enter into the composition of the occipital bone'.<sup>11</sup> A trickle of single case reports of developmental anomalies of the craniovertebral border followed<sup>3</sup> from out of what Karl List called, "the twilight zone between neurology and roentgenology"<sup>18</sup> until, in 1953, McRae and Barnum<sup>18</sup> presented 25 cases of occipitalization of the atlas, and an extensive review. Some thirty years later, Merbs and Euler<sup>10</sup> published a case where not only was the atlas fused to the occiput but cervical vertebrae three and four were also fused. The flattening of the left half of the atlantic posterior arch was curiously reminiscent of the flattened left border of the foramen magnum in the current case (Fig. 4). In 1989 Kalla *et al.*<sup>9</sup> published the first systematic study of genetic predisposition to atlanto-occipital joint anomalies. In a radiographic study of 115 close relatives of their 20 cases they discovered a further 4 cases with the same anomaly. Since then, there has been an avalanche of cases of this rarity,<sup>3,8,12,14-17,21,30-33</sup> probably because detection technology has vastly improved.

Given, from the above, the apparent rarity of atlanto-occipital fusion, one might suspect that more might be out there remaining undetected - that is, they are asymptomatic. Indeed Currarino *et al.*<sup>31</sup> in a study sample of seven patients with congenital anomalies of the posterior arch of the atlas found four to be asymptomatic; Torriani and Lourenço<sup>33</sup> went so far as to say that 'in general such abnormalities are asymptomatic'. On the other hand, Smoker<sup>21</sup> provides a comprehensive list of signs and symptoms of craniocervical junction anomalies, pointing out that atlanto-occipital assimilation invariably results in basilar invagination, and cites Vakili *et al.*,<sup>34</sup> 'in some instances, atlanto-occipital assimilation may be associated with sudden death.' Jayanthi *et al.*<sup>8</sup> are equally cheerful. Nevertheless, atlanto-occipital fusion will inevitably shorten the neck and, as the patient grows older, shrinking of the intervertebral

discs may force the odontoid process upward into the foramen magnum, adding to the compression of the spinal cord which, in the current case, is already compressed posteriorly by the right posterior atlantic arch. Our case's least problem will be her head directed to the right, with limited lateral head movement due to the angulation of the inferior atlantic condyles, followed by, variously, headache, neck pain, numbness and pain in the limbs, weakness, tinnitus, visual disturbances, and lower cranial nerve palsies leading to dysphagia and dysarthria.<sup>8,10,18,30,32</sup>

How did the atlanto-occipital fusion occur in the present case, assuming that the lack of fusion of the right half of the posterior arch with the missing left half makes it unlikely that trauma or infection are causative agents here? The pattern for future development of the vertebral column is set during the third and fourth weeks of intra-uterine life.<sup>15</sup> The caudal part of the fourth occipital somite fuses with the cranial part of the first cervical somite, forming the 'proatlas'.<sup>11</sup> In some lower vertebrates this remains as a separate bone between the occiput and the atlas, but in humans it is assimilated into the occiput as the occipital condyles, and it also forms the apex of the odontoid process.<sup>15</sup> The caudal part of the first cervical sclerotome segment (possibly with some resegmentation from the cranial part of the second cervical somite) forms the whole of the atlas plus the odontoid process of the axis. Sclerocoel formation within this recombined segment separates the odontoid process from the anterior arch of the atlas. Should this separation not occur, the odontoid process would remain fused to the posterior surface of the anterior arch of the atlas - Fig.6 shows that this separation has been only partial.<sup>18,35</sup> The body and neural arch of the axis is then formed from the fusion of the caudal part of the second cervical somite with the cranial part of the third cervical somite. Should an intrasegmental fissure fail to develop, there will be no intervertebral joint. Thus, occipitalization of the atlas arises when the first cervical somite fails to split into its cranial and caudal components. Consequently, the atlas becomes assimilated into the occipital region, because the fourth occipital somite has fused with the entire first cervical somite and the cranial portion of the second cervical somite.<sup>8,15,16,18,36,37</sup> We can now see that segmentation is one of the crucial prerequisites in vertebrate development.<sup>3</sup> The question we are left with is, why does this segmentation fail to occur?

Incidentally the marked asymmetry shown by this skull is also remarkable - if you look solely at the left side (Fig.1), you see the 'square' orbits (breadth 43.34 mm), small mastoid process (length 16.03 mm), and general gracility of a female. If you now look at the right side, starting from the protruding glabella, the rectangular orbit (46.30 mm), the large mastoid process (length 17.50 mm), the dehiscence of the right tympanic plate, the larger vertebral canal, the wider inferior atlantic condyle (14.35 v. 13.55 mm), the bulk of the mandible... the general 'robustness' of the whole presents a 'male' picture - this lady in death has not only given us the opportunity of studying two atlantic anomalies, she has given us all a useful lesson in sex determination as well.

### ACKNOWLEDGEMENT

I acknowledge the kindness of Professor Jules Kieser in allowing me to study this skull.

### REFERENCES

- Menezes AH. Developmental abnormalities of the craniovertebral junction. In: Winn HR. Ed. Youman's neurological surgery. 5<sup>th</sup> edn. Philadelphia: Elsevier, 2004:333-4.
- Esses SI. Textbook of spinal disorders. Philadelphia: JB Lippincott, 1995.
- Al-Motabagani MA, Surendra M. Total occipitalization of the atlas. *Anat Sci Internat* 2006;81:173-180.
- Harcourt BT, Mitchell TC. Occipitalization of the atlas. *J Manipulative Physiol Ther* 1990;13:532-8.
- Macalister A. Notes on the development and variations of the atlas. *J Anat Physiol* 1893;27:519-54.
- Standring S. Ed. Gray's anatomy. The anatomical basis of clinical practice. 40th edn. Edinburgh: Churchill Livingstone, 2008;720.
- Green HLHH. An unusual case of atlanto-occipital fusion. *J Anat* 1915;65:140-4.
- Jayanthi V, Kulkarni R, Kulkarni RN. Atlanto-occipital fusion - report of two cases. *J Anat Soc India* 2003;52:71-3.
- Kalla AK, Khanna S, Singh IP, Sharma S, Schnobel R, Vogel F. A genetic and anthropological study of atlanto-occipital fusion. *Hum Genet* 1989;81:105-12.
- Merbs CF, Euler RC. Atlanto-occipital fusion and spondylolisthesis in an Anasazi skeleton from Bright Angel Ruin, Grand Canyon National Park, Arizona. *Am J Phys Anthropol* 1985;67:381-91.
- Gladstone J, Erichsen-Powell W. Manifestation of occipital vertebræ, and fusion of the atlas with the occipital bone. *J Anat* 1915;49:190-209.
- Iizuka H, Sorimachi Y, Ara T, Nishinome M, Nakajima T, Iizuka Y, Takagishi K. Relationship between the morphology of the atlanto-occipital joint and the radiographic results in patients with atlanto-axial subluxation due to rheumatoid arthritis. *Eur Spine J* 2008;17:826-30.
- Eulderink F, Meijers KAE. Pathology of the cervical spine in rheumatoid arthritis: a controlled study of 44 spines. *J Pathol* 1976;120:91-108.
- Ahmed R, Traynelis VC, Menezes AH. Fusions at the craniovertebral junction. *Childs Nerv System* 2008;24:1209-24.
- Black SM, Scheuer JL. Occipitalization of the atlas with reference to its embryological development. *Int J Osteoarchaeol* 1996;6:189-94.
- Chandraraj S, Briggs CA. Failure of somite differentiation at the cranio-vertebral region as a cause of occipitalization of the atlas. *Spine* 1992;17:1249-51.
- Gholve PA, Hosalkar HS, Ricchetti ET, Pollock AN, Dormans JP, Drummond DS. Occipitalization of the atlas in children: morphological classification, associations, and clinical relevance. *J Bone Joint Surg Am* 2007;89:571-8.
- McRae DL, Barnum AS. Occipitalization of the atlas. *Am J R* 1953;70:23-46.
- Wackenheimer A, Baleriaux D, Lemort M, Bellen P. Occipitalisation of the ventral part and vertebralisation of the dorsal part of the atlas. *J Radiol* 1983;64:425-7.
- Epps HR, Salter RB. Orthopedic conditions of the cervical spine and shoulder. *Pediatr Clin North Am* 1996;43:919-31.
- Smoker WRK. Craniovertebral junction: normal anatomy, craniometry, and congenital anomalies. *Radiographics* 1994;14:255-77.
- Yochum TR, Rowe LJ. Essentials of skeletal radiology. London: Williams and Wilkins, 1987.
- Krogman WM. Sexing skeletal remains. In:

- Krogman WM. Ed. The human skeleton in forensic medicine. Springfield: Charles C. Thomas, 1962;112-22.
24. Stewart TD. Identification by the skeletal structure. In: Camps FE. Ed. Gradwohl's legal medicine. 2<sup>nd</sup> edn. Baltimore: Williams & Wilkins, 1968;123-154.
25. Bass WM. Human Osteology. 3<sup>rd</sup> edn. Columbia: Missouri Archaeological Society, 1987;81-82.
26. Dixon AD, Hoyte DAN, Rönning O. Eds. Fundamentals of craniofacial growth. Boca Raton: CRC Press, 1997;276, 289.
27. Kumar S, Shah AK, Patel AM, Shah UA. CT and MR images of the flat bone osteochondromata from head to foot: A pictorial essay. Indian J Radiol Imaging 2006;16:589-96.
28. Ortner DJ, Putschar WGJ. Identification of pathological conditions in human skeletal remains. Washington: Smithsonian Institution Press, 1981;258.
29. Walker PL, Bathurst RR, Richman R, Gjerdrum T, Andrushko VA. The Causes of Porotic Hyperostosis and Cribra Orbitalia: A reappraisal of the iron-deficiency-anemia hypothesis. Am J Phy. Anthropol 2009;10.1002/ajpa.21031.
30. Nayak S, Vollala VR, Raghunathan D. Total fusion of axis with occipital bone: a case report. Neuroanat 2005;4:39-40.
31. Currarino G, Rollins N, Diehl JT. Congenital defects of the posterior arch of the atlas: a report of seven cases including an affected mother and son. Am J Neuroradiol 1994;15:249-54.
32. Jain VK, Mittal P, Banerji D, Behari S, Acharya R, Chhabra D. Posterior occipitoaxial fusion for atlantoaxial dislocation associated with occipitalized atlas. J Neurosurg 1996;84:559-64.
33. Torriani M, Lourenço JLG. Agenesis of the posterior arch of the atlas. Rev Hosp Clin Fac Med S Paulo 2002;57:73-6.
34. Vakili ST, Aguilar JC, Muller J. Sudden unexpected death associated with atlanto-occipital fusion. Am J Forensic Med Pathol 1985;6:39-43. (Cited by Smoker.<sup>21</sup>)
35. Olbrantz K, Bohrer SP. Fusion of the anterior arch of the atlas and the dens. Skeletal Radiol 1984;12:21-2.
36. Müller F, O'Rahilly R. Segmentation in staged human embryos: the occipitocervical region revisited. J Anat 2003;203:297-315.
37. Rao PV, Mbajjorgu EF, Levy LF. Bony anomalies of the craniocervical junction. Cent Afr J Med 2002;48:17-23.

**Address for correspondence:**

*K J Dennison*

*Department of Anatomy and Structural Biology*

*University of Otago School of Medical Sciences*

*PO Box 913, Dunedin 9054, NEW ZEALAND*

*Telephone: 0064 3 479 7437*

*FAX: 0064 3 479 7254*

*e-mail: [john.dennison@stonebow.otago.ac.nz](mailto:john.dennison@stonebow.otago.ac.nz)*